Intramedullary Spinal Cryptococcoma: A Case Report

Ping-Hong Lai, Jyh Seng Wang,[1] Wei Liang Chen, Huay-Ben Pan, and Chien-Fang Yang

Abstract: Intramedullary spinal cryptococcosis is very rare. We describe a case of intramedullary spinal cryptococcoma at the T12 level in a 60-year-old man who presented with a 3-month history of progressive bilateral lower limb weakness and no obvious immunocompromise. Magnetic resonance (MR) imaging revealed a 1.2 cm diameter mass within the spinal cord at T12 with intermediate signal intensity on T1-weighted images, a slight degree of homogeneous low signal intensity on T2-weighted images, and intense enhancement after infusion of gadopentetate dimeglumine. These findings led to a preoperative diagnosis of intramedullary tumor. After 2 months of postoperative antifungal treatment, the patient's clinical condition had markedly improved. Cryptococcoma should be considered when an enhancing lesion of the spinal cord is found on MR imaging, even in apparently immunocompetent patients. A careful lumbar puncture for cerebrospinal fluid analysis to diagnose cryptococcosis of the central nervous system should be made promptly, as early treatment is associated with a good prognosis.

(J Formos Med Assoc 2001;**100**:776–8*)*

Key words:
cryptococcosis
spinal cord
magnetic resonance imaging

Cryptococcus neoformans is the most common fungal infection of the central nervous system (CNS) [1]. It is seen rarely in healthy individuals and more commonly occurs as an opportunistic infection in immunocompromised patients, patients debilitated by cancer or diabetes, those treated with steroids or chemotherapy, and, most commonly, in patients with AIDS. Although there are many articles on the computerized tomographic and magnetic resonance (MR) imaging characteristics of intracranial cryptococcal infection [1–7], the literature on MR imaging of intramedullary spinal cryptococcoma is limited. This article describes the MR findings of an intramedullary cryptococcoma in a patient with no obvious immunocompromise.

Case Report

A 60-year-old man with no obvious immunocompromise presented with a 3-month history of progressive bilateral lower limb weakness. General physical examination revealed that the man was afebrile, normotensive, oriented, and in no acute distress. Neurologic examination showed the patient's muscle power score was 5 over his upper and 3 over his lower extremities.

On admission, results of chest roentgenography, blood tests, and HIV serology were normal. MR imaging of the thoraco-lumbar spine showed an intramedullary mass at T12. The lesion had intermediate signal intensity on T1-weighted MR images (Fig. 1A). On T2-weighted images, the mass had a slightly homogeneous hypointense signal intensity compared with normal cord, with a high signal surrounding the mass, suggesting perifocal edema (Fig. 1B). T1-weighted contrast-enhanced imaging showed solid enhancement (Fig. 1C). The differential diagnoses of this intramedullary tumor included metastasis, ependymoma, and astrocytoma.

A total laminectomy of T11–L1 and excision of the lesion were performed. An intramedullary whitish mass (1.2 cm in diameter) with hard consistency was noted on gross inspection. Light microscopic examination revealed a picture of cryptococcosis featuring numerous round-to-oval yeast forms surrounded by optically clear capsules (Fig. 2). Mucicarmine stain of the capsule was positive. The cryptococci elicited a granulomatous inflammation with foci of caseous necrosis. Cryptococcal granuloma was diagnosed. Analysis of the cerebrospinal fluid (CSF) obtained during surgery showed a white blood cell count of 2/mm^3, a red blood cell count of

Departments of Radiology and [1]Pathology, Veterans General Hospital-Kaohsiung, National Yang-Ming College, Kaohsiung.
Received: 26 July 2000. Revised: 22 August 2000. Accepted: 6 February 2001.
Reprint requests and correspondence to: Dr. Ping-Hong Lai, Department of Radiology, Veterans General Hospital-Kaohsiung, 386 Ta-Chung First Road, Kaohsiung, Taiwan.

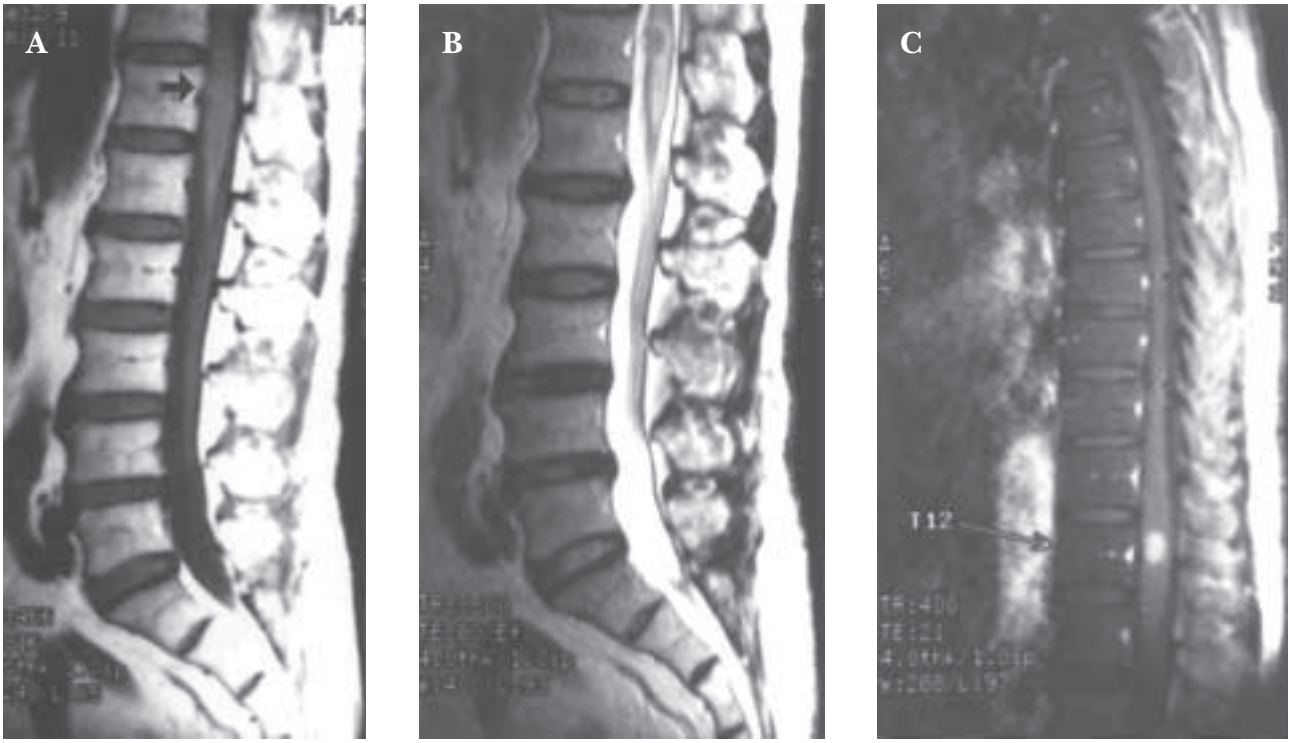

Fig. 1. *Magnetic resonance images of a 60-year-old man with intramedullary spinal cryptococcoma at T12. A) T1-weighted image shows a lesion with intermediate signal intensity (arrow) at T12. B) T2-weighted image reveals the mass as a slightly homogeneous hypointense signal compared with normal cord, with a high signal surrounding the mass, suggesting perifocal edema. C) T1-weighted contrast-enhanced image shows intense enhancement of the mass.*

20/mm^3, a total protein concentration of 50 mg/dL, and a glucose concentration of 46 mg/dL. Cryptococcal antigen was present. India ink preparation and culture of the CSF were positive for *C. neoformans*. CSF bacterial and acid-fast bacillus cultures were negative. Venereal Disease Research Laboratory test of the CSF was nonreactive. CSF cytology was negative for malignant cells. Postoperative therapy with fluconazole and amphotericin B was instituted for 6 weeks. The patient's symptoms gradually improved and he was discharged without neurologic deficit after 2 months of rehabilitation.

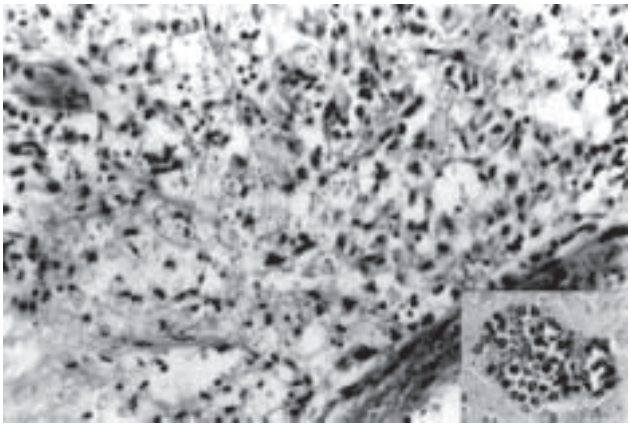

Fig. 2. *Numerous round-to-oval yeast forms of cryptococci with granulomatous inflammation. (Haematoxylin and eosin, x 240) Inset: Yeast-form cryptococci showing mucin-positive capsules. (Mucicarmine, x 240).*

Discussion

C. neoformans, the only *Cryptococcus* species known to be pathogenic in humans, can be isolated from soil contaminated by bird excreta. It is thought that most human infections are acquired through inhalation. CNS infection by *C. neoformans* is usually the result of hematogenous dissemination from a pulmonary focus. Immunosuppressed or debilitated patients are at a greater risk of cryptococcal infection than healthy individuals [1–3].

Onset of this illness is usually insidious, but may be acute in patients who are significantly immunocompromised. Presentation may include headache and altered mental status, followed by cranial nerve abnormalities [1–3, 8]. Untreated, the disease is fatal. Our patient presented with progressive lower limb weak-

ness and no intracranial symptoms such as nausea, vomiting, and headache. Although CNS cryptococcal infection is secondary to inhalation (the primary mode of entry) of the organism, it has also been reported that pulmonary disease is not usually evident clinically [1, 2]. No pulmonary cryptococcal focus could be identified in our patient.

Meningitis is the most common manifestation of CNS cryptococcosis [1, 8]. Infection may then extend from basal cisterns into the brain substance via perivascular Virchow-Robin spaces [2, 4–6]. Typical MR imaging findings of CNS cryptococcosis include meningitis, dilated perivascular spaces, and cryptococcomas in the brain [1, 2, 4–7]. Immunocompetent patients are more likely to present with cryptococcal mass lesions known as cryptococcomas [1]. Most intracranial cryptococcomas are less than 3 mm in diameter, although some may be several centimeters in diameter [2, 4, 6]. They appear as nonspecific signal abnormalities on MR imaging [1, 2, 6].

Intraspinal cryptococcosis is rare, either in the spinal cord [9], meninges [10], or epidural space [11]. Ramamurthi and Anguli reported a patient with bilateral lower limb weakness that progressed for several months [9]. Myelography through the cisternae showed obstruction at T2, and a circumscribed intramedullary cryptococcal granuloma (1.5 cm in diameter) at T3 was described. The postoperative period was smooth and the patient was in good health throughout follow-up of more than 1 year. Spinal cord cryptococcoma is a distinct and extremely rare pathologic entity clinically indistinguishable from neoplasm [9]. In our patient, this condition manifested as an intense enhancing mass at the T12 level of the spinal cord, and the normal immune status of the patient may have accounted for the enhancement of the lesion.

Early diagnosis of CNS cryptococcosis is essential. CSF analysis may show increased protein and lymphocytes, and decreased glucose. India ink preparations are positive in about 60% of cases, and latex agglutination tests are positive in more than 90%. In patients with AIDS, the CSF may be entirely normal except for the presence of yeast cells [12]. Mortality is high in untreated patients with cryptococcal infection. The mortality rate, even in immunocompetent individuals, may be as high as 20 to 40% if treatment with antifungal agents is delayed. The clinical manifestations of patients with intracranial cryptococcomas do not significantly differ from those in patients without mass lesions, but the mortality is higher [13].

In summary, cryptococcoma is an enhancing lesion of the spinal cord, even in apparently immunocompetent patients. A careful lumbar puncture should be made promptly for CSF analysis to diagnose cryptococcosis of the CNS, as early treatment is predictive of a good prognosis.

References

1. Ostrow TD, Hudgins PA: Magnetic resonance imaging of intracranial fungal infections. *Top Magn Reson Imaging* 1994;6:22–31.
2. Mathews VP, Alo PL, Glass JD, et al: AIDS-related CNS cryptococcosis: radiologic–pathologic correlation. *Am J Neuroradiol* 1992;13:1477–86.
3. Popovich MJ, Arthur RH, Helmer E: CT of intracranial cryptococcosis. *Am J Neuroradiol* 1990;11:139–42.
4. Tien RD, Chu PK, Hesselink JR, et al: Intracranial cryptococcosis in immunocompromised patients: CT and MR findings in 29 cases. *Am J Neuroradiol* 1990;12:283–9.
5. When SM, Heinz ER, Burger PC, et al: Dilated Virchow-Robin spaces in meningitis associated with AIDS: CT and MR findings. *J Comput Assist Tomogr* 1989;13: 756–62.
6. Andreula CF, Burdi N, Carella A: CNS cryptococcosis in AIDS: spectrum of MR findings. *J Comput Assist Tomogr* 1993;17:438–41.
7. Patronas NJ, Makariou EV: MRI of choroidal involvement in intracranial cryptococcosis. *J Comput Assist Tomogr* 1993;17:547–50.
8. Shih CC, Chen YC, Chang SC, et al: Cryptococcal meningitis in non-HIV-infected patients. *Q J Med* 2000;93:245–51.
9. Ramamurthi B, Anguli VC: Intramedullary cryptococcic granuloma of the spinal cord. *J Neurosurg* 1954;11:622–4.
10. Woodall WC, Bertorini TE, Bakhtian BJ, et al: Spinal arachnoiditis with *Cryptococcus neoformans* in a nonimmunocompromised child. *Pediatr Neurol* 1990;6:206–8.
11. Rao SB, Rao KS, Dinakar I: Spinal extradural cryptococcal granuloma. *Neurology* 1970;11:1066–70.
12. dos Reis-Filho JB, Matas SL, Fischman O, et al: Comparison between CSF samples from AIDS and non AIDS patients with neurocryptococcosis. *Rev Instit Med Trop Sao Paulo* 1994;36:225–30.
13. Chotmongkol V, Jitpimolmard S: Cryptococcal intracranial mass lesions associated with cryptococcal meningitis. *Southeast Asian J Trop Med Public Health* 1993;24:94–8.