Preoperative Diagnosis and Localization of Aldosterone-Producing Adenoma by Adrenal Venous Sampling After Administration of Metoclopramide

Kwan-Dun Wu, Tsou-Song Liao, Yung-Ming Chen, Min-Kun Lai,[1] Shyh-Jye Chen,[2] Chen-Tau Su,[2] Tzong-Shinn Chu, Ching-Chung Chang, and Bor-Shen Hsieh

Background and purpose: Adrenal venous sampling is the most reliable test to distinguish aldosterone-producing adenoma (APA) from idiopathic hyperaldosteronism (IHA). The diagnostic accuracy can be improved by administration of adrenocorticotropin to minimize pulsatile secretion of aldosterone. Metoclopramide (MCP), a dopamine antagonist, can increase aldosterone secretion promptly without affecting cortisol secretion. This study investigated the diagnostic accuracy of adrenal venous sampling after MCP injection for the preoperative diagnosis and localization of APA.

Methods: Prospective diagnosis and adrenalectomy was based on adrenal venous sampling in 23 patients with a diagnosis of primary aldosteronism. Plasma aldosterone concentrations from adrenal veins and the inferior vena cava were measured before and 30 minutes after intravenous administration of 10 mg MCP. The ratio of bilateral adrenal venous aldosterone concentrations after MCP was used for diagnosis as follows: a ratio greater than 5 indicated APA, less than 3 indicated IHA, and 3–5 indicated an intermediate diagnosis.

Results: Catheterization of the right adrenal vein was unsuccessful in three patients. Twelve of 13 patients with an aldosterone ratio greater than 5 after MCP underwent unilateral adrenalectomy, and APA was confirmed in 11 of these patients. One patient with an intermediate diagnosis also had surgically confirmed APA. Six patients had a ratio less than 3. Before MCP administration, 10 of 13 patients with APA had a ratio greater than 5, and three patients had a ratio between 3 and 5; one patient with IHA had a ratio greater than 5. MCP improved the diagnosis of APA to an accuracy of 92% (12/13). Correct diagnosis of APA based on computerized tomography (CT) was 85% (11/13). There was discordance between the findings of adrenal venous sampling and CT in four of 20 patients.

Conclusions: Administration of MCP to stimulate aldosterone secretion during adrenal venous sampling can improve the accuracy of differential diagnosis between APA and IHA.

(J Formos Med Assoc 2001;**100**:598–603*)*

Key words:
primary aldosteronism
aldosterone-producing adenoma
adrenal venous sampling
metoclopramide
preoperative diagnosis

Primary aldosteronism, a curable disease of hypertension, is readily diagnosed in patients with hypertension, hypokalemia, unsuppressible aldosterone secretion, and persistent low levels of plasma renin. However, preoperative differential diagnosis remains difficult between aldosterone-producing adenoma (APA), for which adrenalectomy is curative in up to 75% of cases, and idiopathic hyperaldosteronism (IHA), the next most common subtype of primary aldosteronism, which is seldom treated with unilateral or bilateral adrenalectomy [1, 2]. The differential diagnosis between these two subtypes is routinely based on imaging studies, mainly computerized

Departments of Medicine, [1]Urology, and [2]Radiology, National Taiwan University Hospital, Taipei.
Received: 20 April 2001. Revised: 17 May 2001. Accepted: 10 July 2001.
Reprint requests and correspondence to: Dr. Bor-Shen Hsieh, Division of Nephrology, Department of Medicine, National Taiwan University Hospital, 7 Chung-Shan South Road, Taipei, Taiwan.

tomography (CT) [3–5]. Careful screening techniques have improved the rate of early diagnosis of primary aldosteronism. Adenomas in such early diagnosed cases may be too small to be detected on CT. On the other hand, nonfunctional nodules of the adrenal glands visible on high-resolution images may confound the differentiation between APA and IHA [4, 6, 7]. Adrenal scintigraphy with iodomethylnorcholesterol (NP-59) shows a good correlation of function with anatomic abnormalities. Its sensitivity, however, is poor in adenomas of less than 1.5 cm [8]. Other tests, such as postural study and measurement of plasma 18-hydroxycorticosterone, may provide adjuvant information supporting the diagnosis, but the diagnostic accuracy of these tests is not more than 85% [2]. Bilateral adrenal venous sampling remains the most accurate and definitive test for distinguishing unilateral APA from IHA [1, 6, 7, 9–11].

In adrenal venous sampling, establishment of unilateral hypersecretion of aldosterone is usually based on comparison of the aldosterone ratio or aldosterone/cortisol (A/C) ratio between bilateral adrenals after adrenocorticotropin (ACTH) infusion [1, 7, 9, 11]. ACTH administration increases aldosterone secretion from the abnormal adrenal tissues but not from the contralateral gland of patients with APA. The discrepancy in aldosterone secretion from the bilateral adrenal glands of patients with APA is, therefore, exaggerated. With ACTH stimulation, the diagnostic accuracy increased, especially for diagnosis of IHA [11].

Aldosterone secretion has been shown to be regulated by the dopaminergic system in patients with primary aldosteronism as well as in normal subjects [12]. Plasma aldosterone concentrations significantly increase after injection of metoclopramide (MCP) in patients with APA and IHA [13–16]. However, this effect disappeared in patients with APA if the test was performed within 1 week after unilateral adrenalectomy [14]. This observation leads to the speculation that MCP increases aldosterone secretion from APA and the hyperplasic adrenals in IHA, but not the contralateral normal adrenal gland of patients with APA. Accordingly, it should be feasible to use MCP in bilateral adrenal venous sampling to distinguish between APA and IHA. In this study, we performed bilateral adrenal venous sampling before and after MCP injection to determine the subtypes of primary aldosteronism and localize the APA lesion.

Materials and Methods

Twenty-three patients (13 female, 10 male), aged 31 to 73 years, with a diagnosis of primary aldosteronism were enrolled in the study. Hypokalemia was found in 20 of these patients. All patients had abnormally high ratios of plasma aldosterone concentration (PAC) to plasma renin activity (PRA) in a random blood sample. For the differential diagnosis between APA and IHA, all patients underwent postural study, adrenal CT scan, and bilateral adrenal venous sampling with MCP test. The patients ingested a 150-mmol sodium and 90-mmol potassium diet each day for at least 3 days before examinations. On the day of the postural study, a blood sample was obtained at 7 am after overnight recumbence. A second sample was obtained after 3 hours in an upright posture and ambulation. An increase in PAC greater than 30% above baseline indicated a positive result.

Adrenal venous sampling

Bilateral adrenal veins were catheterized simultaneously via both femoral veins, using No. 7F Goodale-Luvin catheters. The catheter position was verified by injection of a small amount of contrast medium. The left adrenal vein was successfully catheterized in all patients. Right adrenal sampling could not be obtained in three patients due to failure to catheterize the right adrenal vein. Selective venous samples for measurements of aldosterone and cortisol concentrations were obtained from the following sites: bilateral adrenal veins, inferior vena cava (IVC) above the drainage of the adrenal veins, and antecubital vein (PB). Blood samples were collected in heparinized tubes by free drip from the catheters. After baseline sampling, a bolus intravenous injection of 10 mg MCP was administered. A second set of blood samples was collected from the same sites 30 minutes after MCP injection. The differential diagnosis between APA and IHA made from the adrenal venous samples was based on comparison of the change in PAC after MCP injection. APA was highly suspected when PAC from one adrenal vein was 5 times greater than that of the contralateral adrenal vein after MCP injection. Diagnosis of IHA was made when this aldosterone ratio was less than 3. A ratio of between 3 and 5 was considered intermediate for APA, but strongly supported APA when the PAC from the unaffected adrenal vein was lower than that from the PB or the IVC after MCP injection.

The concentrations of aldosterone and cortisol were measured by radioimmunoassay (RIA) using commercial kits as described previously [15]. Statistical analysis was performed with paired and unpaired *t*-tests using the Stat-View software package (Abacus Concepte, Inc, Berkeley, CA, USA). Statistical significance was recognized at the 5% level.

CT scan

Adrenal CT scans were performed using an electron beam CT scanner (C-150L; Imatron, South San

Francisco, CA, USA). Images were independently reviewed by two radiologists who were experienced in adrenal imaging. They were informed that all patients were diagnosed with primary aldosteronism, but did not have other clinical data. APA was diagnosed when a unilateral nodule (> 5 mm) was present. IHA was diagnosed based on the presence of bilateral nodules, multiple unilateral nodules, or normal adrenal glands.

Operation

Surgical exploration was performed on the basis of adrenal venous sampling regardless of the findings on CT scan. Thus, 14 patients underwent unilateral adrenalectomy, and the specimen was examined histologically. Patients were followed for at least 6 months after surgery to determine the curability of the disease.

Results

Based on the CT findings, 12 patients were diagnosed with APA and seven patients with IHA. Diagnosis could not be made in the remaining four patients because the two radiologists could reach no agreement. Positive posture study was observed in one patient diagnosed with APA and four with IHA.

No complications of adrenal catheterization and no adverse effects of MCP injection occurred. Catheterization of the right adrenal vein was not successful in three patients. Two of these patients had hypersecretion of aldosterone from the left adrenal vein. Their postural studies were positive and CT scans were diagnostic for IHA. Surgery was not performed in these two patients. In the third patient, CT identified a left adrenal adenoma and hypersecretion of aldosterone from the left adrenal gland was noted. APA was diagnosed surgically in this patient.

After administration of MCP, PAC in the PB (PAC_{PB}) increased significantly (75.5 ± 14.7 *vs* 133.5 ± 20.0 ng/dL, $p < 0.01$) by various degrees ranging from 0.6- to 6.6-fold (mean, 1.7-fold) of the basal level. After MCP injection, 13 patients had an aldosterone ratio greater than 5, one patient had a ratio indicating intermediate diagnosis, and six patients had a ratio less than 3 (Figure). All patients with a diagnosis of IHA had an aldosterone ratio less than 3 before MCP injection, except for one patient who had an aldosterone ratio of 10.8. The PAC_{PB} in patients with IHA was lower than that in patients with APA (23.6 ± 3.4 *vs* 91.7 ± 20.0 ng/dL, $p = 0.042$), but this difference was not found after MCP injection (66.0 ± 17.3 *vs* 110.5 ± 23.0 ng/dL, $p = 0.25$). In patients with a diagnosis of IHA, the PAC in

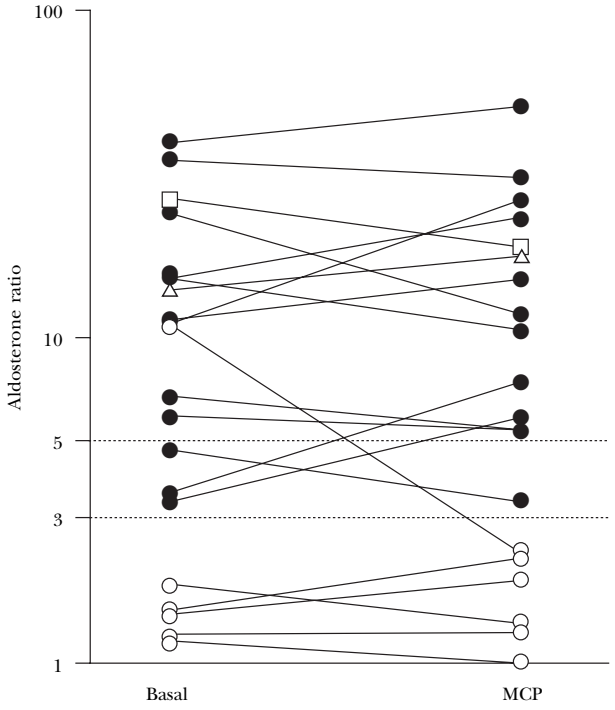

Figure. *Ratio of plasma aldosterone concentrations between bilateral adrenal veins before and after metoclopramide (MCP) administration. Thirteen patients with an aldosterone ratio greater than 5 after MCP administration underwent unilateral adrenalectomy; 12 patients had pathologically proven aldosterone-producing adenoma (APA) (●) and one patient (Δ) had histologically proven cortical hyperplasia. One patient with a diagnosis of APA (□) and six patients with a diagnosis of idiopathic hyperaldosteronism (○) did not undergo surgery.*

both adrenal veins increased significantly after MCP administration (Table). The PAC in the adenomatous adrenal vein in patients with a diagnosis of APA was marginally increased by MCP administration; MCP injection did not change the PAC in the contralateral adrenal vein.

After MCP injection, the PAC from the contralateral adrenal vein of patients with APA was lower than the PAC_{PB} and that of the IVC ($p = 0.052$ and 0.039, respectively), although the difference was not significant before MCP administration ($p = 0.14$ and 0.11, respectively). Eleven patients with APA had an aldosterone concentration in the contralateral adrenal vein lower than that in the IVC. When PAC was divided by cortisol concentration (A/C ratio), the ratio after MCP injection was also higher in the PB than in the contralateral adrenal vein (10.0 ± 2.3 *vs* 3.4 ± 0.5, $p < 0.01$). There was no change in cortisol concentrations from various sampling sites after MCP injection. The adenomatous adrenal veins had higher cortisol concentrations than the contralateral adrenal veins, both before and after MCP injection ($p < 0.01$). Cortisol

Table. Concentrations of aldosterone and cortisol in adrenal veins before and after administration of metoclopramide in patients with diagnoses of aldosterone-producing adenoma (APA) and idiopathic hyperplasia (IHA) based on adrenal venous sampling

Diagnosis*		Before	After	*p*-value
APA (n = 14)				
Adenoma side†	Aldosterone (ng/L)	514.1 ± 109.6	811.3 ± 228.0	0.060
	Cortisol (μg/dL)	55.6 ± 12.1	69.9 ± 13.4	0.168
Contralateral side	Aldosterone (ng/L)	68.7 ± 23.6	70.5 ± 18.2	0.871
	Cortisol (μg/dL)	16.3 ± 2.8	29.1 ± 10.4	0.222
IHA (n = 6)				
Right side	Aldosterone (ng/L)	180.9 ± 67.8	368.7 ± 68.6	< 0.001
	Cortisol (μg/dL)	34.6 ± 11.5	37.8 ± 14.4)	0.800
Left side	Aldosterone (ng/L)	143.3 ± 65.8	353.6 ± 102.5	0.027
	Cortisol (μg/dL)	29.0 ± 10.6	38.0 ± 15.9	0.258

*Differentiation between APA and IHA based on aldosterone ratio between bilateral adrenal veins, with a cut-off value of 3. †11 patients had a higher PAC from the left adrenal vein than that from the right adrenal vein, the others *vice versa*.

concentrations in the adrenal veins in patients with IHA were not different from those in patients with APA, either in the adenomatous or contralateral veins. A positive correlation was noted between cortisol concentrations and PAC in the adrenal veins in patients with IHA, both before and after MCP injection (r = 0.85, $p < 0.01$). A similar correlation was also found in the adenomatous adrenal veins in patients with APA (r = 0.75, p = 0.002 before MCP; r = 0.65, p = 0.011 after MCP).

Thirteen patients who had an aldosterone ratio greater than 3 after MCP injection underwent unilateral adrenalectomy; among them, 12 had surgical evidence of adrenal cortical adenoma. One patient with a diagnosis of APA did not undergo any operation for the tumor. The adenomas were less than 1 cm in four patients. All of these patients achieved a normal blood pressure and a normal PAC/PRA ratio after excision of the adrenal tumor. Two patients with APA had an aldosterone ratio between 3 and 5 before MCP injection; the others had a ratio above 5. Left APA was diagnosed based on aldosterone ratio in one patient whose CT interpretation was indeterminate. Her PAC decreased from 34.7 to 24.3 ng/dL after ambulation for 3 hours. Surgery was performed and the excised left adrenal gland revealed a hypertrophied cortex. After operation, her PRA remained suppressed, with a PAC/PRA ratio of 77. Her blood pressure did not normalize after surgery.

The overall false-positive rate for this series was 8% (1/13). Without MCP, the false-positive rate for diagnosis of APA by adrenal venous sampling would have been 14% (2/14) if an aldosterone ratio of 3 was chosen as the cut-off value. The accuracy of aldosterone ratio after MCP injection for diagnosis of APA was 92% (12/13) if a value of the ratio greater than 3 was used as the diagnostic criterion. However, the specificity of this method could not be evaluated because those patients with a diagnosis of IHA did not undergo surgery. The rate of diagnosis of APA based on CT findings was 85% (11/13). APA was diagnosed based on CT scan in two patients with a diagnosis of IHA based on sampling data. Therefore, a discrepancy existed between the diagnosis based on adrenal venous sampling and CT scan in four of 20 patients. Six patients had a positive postural study. Among patients with surgically proven APA, only one patient had a positive postural study, compared with five of nine patients with a diagnosis of IHA. PAC was not different between patients with APA and IHA, either before or after ambulation. The PAC/PRA ratio before ambulation in patients with APA was higher than that in patients with IHA (208 ± 39 *vs* 82 ± 12 ng/dL, p = 0.025); no difference was found after ambulation (267 ± 141 *vs* 118 ± 27 ng/dL, p = 0.46). If a negative stimulation was considered diagnostic for APA, the sensitivity and specificity were 76 and 83%, respectively.

Discussion

A significant increase in plasma aldosterone concentrations after intravenous administration of MCP has been observed in normal subjects and patients with primary aldosteronism [13–16]. The responsiveness to MCP is different among various subtypes of primary aldosteronism [12, 15]. Our previous study demonstrated that the increase in PAC_{PB} after MCP injection in APA was inversely related to the percentage of zona fasciculata-like cells in adenomas [17]. In contrast to the observations of Naruse et al [16], the present study

found that the increase in PAC_{PB} after MCP injection was more significant in patients with IHA than in those with APA. Nevertheless, the increase in PAC_{PB} in our patients with APA was compatible with the findings of a previous study from Japan [15]. The discrepancy may have resulted from a different histology of APA and/or sodium status of patients.

MCP enhances aldosterone secretion only from abnormal aldosterone-producing tissues, not from contralateral glands of patients with APA. In this context, the aldosterone ratio between bilateral venous samples after MCP injection can be used to distinguish between APA and IHA. Several studies of adrenal venous sampling have used an aldosterone ratio of 3 as a cut-off point for differentiation between APA and IHA [1, 6, 9, 11]. Using MCP injection instead of ACTH infusion, we obtained a diagnostic accuracy for APA (92%, 12 of 13 patients) compatible with previous studies [1, 2, 7, 9]. The false-negative rate for this technique could not be determined because the decision to perform surgical intervention, as in previous studies, was based on the findings of adrenal sampling. In the present study, IHA was diagnosed in eight of 23 patients. This prevalence is higher than in other reports, in which hyperplasia was observed in one-fourth of patients with primary aldosteronism. However, the prevalence of IHA has been shown to increase up to 45% with the use of careful screening techniques [2].

During adrenal venous sampling, ACTH is usually administered to minimize artifacts due to pulsatile secretion of aldosterone. After ACTH infusion, both aldosterone and cortisol concentrations increase from the ipsilateral gland of patients with APA and both glands of IHA. Theoretically, ACTH does not increase aldosterone secretion from the contralateral gland of patients with APA, but this is not always true. A several-fold increase (up to 20-fold) in aldosterone secretion from the contralateral gland in patients with APA has been observed [11]. Our data showed that the increase in aldosterone by MCP from the contralateral gland of APA was less than twofold. The cortisol concentration is usually measured to correct the effect of ACTH on aldosterone secretion, but in most cases the ratio of aldosterone concentrations alone was adequate to localize the lesion [1, 10, 11]. Tokunaga et al demonstrated that the A/C ratio after ACTH administration had no advantage over aldosterone ratio for the diagnosis of APA or IHA [11]. It has been proposed that the plasma aldosterone surges in primary aldosteronism are due to a loss of inhibitory dopaminergic control [18]. If so, the rapid and sustained effect of MCP on aldosterone secretion has the advantage of minimizing the pulsatile secretion of aldosterone. Although measurements of cortisol concentration in adrenal venous samples can verify the catheter placement and correct the dilution factors, we demonstrated that simultaneous sampling from IVC after MCP without measuring cortisol concentrations was sufficient to achieve these goals.

In fact, false-positive identification of unilateral adenomas has been reported when A/C ratios were compared. In the study of McLeod et al, four of 11 patients with surgically proven IHA had A/C ratios greater than 3 and were interpreted to have unilateral adrenal lesions [19]. A similar observation was also reported by Weinberger et al in five of 11 patients [1]. A distinct subset of hyperplasia characterized by unilateral-predominant adrenal gland hyperfunction has been described [19–21]. This subset is potentially curable by unilateral adrenalectomy. One of our patients had unilateral-predominant excessive aldosterone secretion with pathologically proven IHA and demonstrated unilateral-predominant excessive aldosterone secretion. However, unilateral adrenalectomy did not cure her hypertension and hyperaldosteronism.

In our patients with APA, cortisol secretion from the ipsilateral adrenal gland was higher than from the contralateral adrenal gland. A similar observation was also made in previous studies [10, 11, 22]. The reason for this finding is not clear, but we have demonstrated that in APA, the expression of aldosterone synthase and 11β-hydroxylase, which are responsible for the synthesis of aldosterone and cortisol, respectively, was positively correlated at the transcriptional level [17]. Therefore, it is possible that ACTH infusion in such cases may result in no difference in A/C ratios between the adenomatous and contralateral gland. In the present study, no such positive correlation between aldosterone and cortisol secretion was found from the adenomas after MCP administration.

Most clinicians rely on CT scan or magnetic resonance imaging to distinguish APA from IHA. Despite the availability of high-resolution scanning, which may detect microadenomas smaller than 10 mm, the possibility of a false-positive diagnosis of hyperplasia is not decreased because small incidental nodules can also be found by such imaging [6, 11]. Two of our patients with surgically diagnosed APA were misdiagnosed with IHA based on CT findings. This suggests that all patients with bilateral nodules on CT scan should undergo adrenal venous sampling. Anomalous postural decline of aldosterone is a valuable adjuvant to the diagnosis of APA. The accuracy in the present study was 80%, which is consistent with a previous report [2]. The response of aldosterone to upright posture in APA may be variable in adenomas with different histology. It has been demonstrated that patients with an adenoma composed of less zona-fasciculata-like cells usually gave positive results on posture study [23]. Salt intake may also influence the result of the posture test. A high-sodium diet may attenuate the response in IHA, and a low-sodium diet may augment the response in some cases of APA [24].

For intense stimulation of both aldosterone and cortisol, a bolus of ACTH is usually followed by continuous infusion for 15 to 30 minutes. Although short-term administration of ACTH, even in massive doses, is generally not harmful, hypersensitivity and anaphylactic reactions have been reported [25]. A bolus of 10 mg MCP can induce a prompt increase in aldosterone, and the dose causes no adverse effects. In summary, we demonstrated that adrenal sampling after MCP injection had similar diagnostic accuracy for APA compared with ACTH injection. Measurement of cortisol to verify the catheter placement is not necessary when sampling is also obtained from the IVC after MCP injection. The test is very simple, and has a lower cost and adverse event ratio than ACTH.

ACKNOWLEDGMENTS: This research was supported in part by grants NSC85-2332-B002-249 (to KD Wu) from the National Science Council, Taiwan. The authors are indebted to FF Hsieh for her excellent assistance in sample and data collections.

References

1. Weinberger MH, Grim CE, Hollifield JW, et al: Primary aldosteronism: diagnosis, localization and treatment. *Ann Intern Med* 1979;90:386–95.
2. Young WF Jr, Hogan MJ, Klee GG, et al: Primary aldosteronism: diagnosis and treatment. *Mayo Clin Proc* 1990;65:96–110.
3. Linde R, Coulam C, Battino R, et al: Localization of aldosterone-producing adenoma by computed tomography. *J Clin Endocrinol Metab* 1979;49:642–5.
4. Radin DR, Manoogian C, Nadler JL: Diagnosis of primary hyperaldosteronism: importance of correlating CT findings with endocrinologic studies. *Am J Roentgenol AJR* 1992;158:553–7.
5. Sheaves R, Goldin J, Reznek RH, et al: Relative value of computed tomography scanning and venous sampling in establishing the cause of primary hyperaldosteronism. *Eur J Endocrinol* 1996;134:308–13.
6. Young WF Jr, Stanson AW, Grant CS, et al: Primary aldosteronism: adrenal venous sampling. *Surgery* 1996; 120:913–20.
7. Doppman JL, Gill JR Jr, Miller DL, et al: Distinction between hyperaldosteronism due to bilateral hyperplasia and unilateral aldosteronoma: reliability of CT. *Radiology* 1992;184:677–82.
8. Normura K, Kusakabe K, Maki M, et al: Iodomethylnorcholesterol uptake in an aldosteronoma shown by dexamethasone-suppression scintigraphy: relationship to adenoma size and functional activity. *J Clin Endocrinol Metab* 1990;71:825–30.
9. Dunnick NR, Doppman JL, Mills SR, et al: Preoperative diagnosis and localization of aldosteronomas by measurement of corticosteroids in adrenal venous blood. *Radiology* 1979;133:331–3.
10. Ma JTC, Wang C, Lam KSL, et al: Fifty cases of primary hyperaldosteronism in Hong Kong Chinese with high frequency of periodic paralysis: evaluation of techniques for tumor localization. *Q J Med* 1986;61:1021–37.
11. Tokunaga K, Nakamura H, Marukawa T, et al: Adrenal venous sampling analysis of primary aldosteronism: value of ACTH stimulation in differentiation of adenoma and hyperplasia. *Eur Radiol* 1992;2:223–9.
12. Cuche JL: Dopaminergic control of aldosterone secretion, state of the art review. *Fundam Clin Pharmacol* 1988;2:327–39.
13. Ganguly A, Pratt J, Weinberger MH, et al: Differing effects of metoclopramide and adrenocorticotropin on plasma aldosterone levels in glucocorticoid-suppressible hyperaldosteronism and other forms of hyperaldosteronism. *J Clin Endocrinol Metab* 1983;57:388–92.
14. Hsieh BS, Kuo YM, Wu KD, et al: Aldosterone response to dopamine antagonist in primary aldosteronism. *J Nephrol ROC* 1988;2:19–24.
15. Mune T, Morita H, Yasuda K, et al: Reduced response to metoclopramide and anomalous rising response to upright posture of plasma aldosterone concentration in Japanese patients with aldosterone-producing adenoma. *J Clin Endocrinol Metab* 1993;77:1020–7.
16. Naruse M, Naruse K, Yoshimoto T, et al: Dopaminergic regulation of aldosterone secretion: its pathophysiologic significance in subsets of primary aldosteronism. *Hypertens Res* 1995;18(Suppl 1):S59–S64.
17. Wu KD, Chen YM, Chu JS, et al: Zona fasciculata-like cells determine the response of plasma aldosterone to metoclopramide and aldosterone synthase messenger ribonucleic acid level in aldosterone-producing adenoma. *J Clin Endocrinol Metab* 1995;80:783–9.
18. Kuchel O, Buu NT, Vecesi P, et al: Are plasma aldosterone surges in primary aldosterone due to a loss of an inhibitory dopaminergic control? *J Clin Endocrinol Metab* 1980;51:337–44.
19. McLeod MK, Thompson NW, Gross MD, et al: Idiopathic aldosteronism masquerading as discrete aldosterone-secreting adrenal cortical neoplasm among patients with primary aldosteronism. *Surgery* 1989;106:1161–8.
20. Ganguly A, Zager PG, Luetscher JA: Primary aldosteronism due to unilateral adrenal hyperplasia. *J Clin Endocrinol Metab* 1980;51:1190–4.
21. Banks WA, Kastin AJ, Biglieri EG, et al: Primary adrenal hyperplasia: a new subset of primary hyperaldosteronism. *J Clin Endocrinol Metab* 1984;58:783–5.
22. Tunny TJ, Klemm SA, Gordon RD: Some aldosterone-producing adrenal tumors also secrete cortisol, but present clinically as primary aldosteronism. *Clin Exp Pharmacol Physiol* 1990;17:167–71.
23. Gordon RD, Hamlet SM, Tunny TJ, et al: Aldosterone-producing adenomas responsive to angiotensin pose problems in diagnosis. *Clin Exp Pharmacol Physiol* 1987;14:175–9.
24. Hsieh BS, Chen WY, Yen TS, et al: Primary aldosteronism. Part II: biochemical features. *J Formos Med Assoc* 1979;78:754–60.
25. McEvoy GK, ed. *AHFS Drug Information.* Bethesda: the American Society of Health-System Pharmacists, Inc. 1997:1882–3.